



HAL
open science

Computed Tomography Description of the Uncinate Process Angulation in Patients With Cystic Fibrosis and Comparison With Primary Ciliary Dyskinesia, Nasal Polyposis, and Controls

Rémi Hervochon, Natacha Teissier, Jean-Robert Blondeau, Natacha Remus, Laurence Bassinet, Florence Canoui-Poitrine, Thierry van den Abbeele, Virginie Prulière-Escabasse

► To cite this version:

Rémi Hervochon, Natacha Teissier, Jean-Robert Blondeau, Natacha Remus, Laurence Bassinet, et al.. Computed Tomography Description of the Uncinate Process Angulation in Patients With Cystic Fibrosis and Comparison With Primary Ciliary Dyskinesia, Nasal Polyposis, and Controls. *Ear Nose and Throat Journal*, 2019, 98 (2), pp.89 - 93. 10.1177/0145561319828645 . hal-04155503

HAL Id: hal-04155503

<https://hal.u-pec.fr/hal-04155503>

Submitted on 7 Jul 2023

HAL is a multi-disciplinary open access archive for the deposit and dissemination of scientific research documents, whether they are published or not. The documents may come from teaching and research institutions in France or abroad, or from public or private research centers.

L'archive ouverte pluridisciplinaire **HAL**, est destinée au dépôt et à la diffusion de documents scientifiques de niveau recherche, publiés ou non, émanant des établissements d'enseignement et de recherche français ou étrangers, des laboratoires publics ou privés.

Computed Tomography Description of the Uncinate Process Angulation in Patients With Cystic Fibrosis and Comparison With Primary Ciliary Dyskinesia, Nasal Polyposis, and Controls

Rémi Hervochon, MD, MSc¹, Natacha Teissier, MD, PhD², Jean-Robert Blondeau, MD³, Natacha Remus, MD⁴, Laurence Bassinet, MD⁵, Florence Canoui-Poitrine, MD, PhD^{6,7,8}, Thierry Van Den Abbeele, MD, PhD², and Virginie Prulière-Escabasse, MD, PhD^{1,7,8}

Ear, Nose & Throat Journal
2019, Vol. 98(2) 89–93
© The Author(s) 2019
Article reuse guidelines:
sagepub.com/journals-permissions
DOI: 10.1177/0145561319828645
journals.sagepub.com/home/ear



Abstract

Background: There is a medial bulging of the lateral nasal wall in patients with cystic fibrosis (CF). **Aims:** Uncinate process (UP) angulation measurements in patients and controls to objectify this bulging. **Materials and Methods:** Thirty CF, 17 primary ciliary dyskinesia (PCD), 13 chronic rhinosinusitis with polyps (CRSwP), and 30 controls were included. Angles were measured bilaterally on computed tomography (CT) scans: A, B, C on coronal sections, D and E on axial sections. Angle A was between the UP and the orbit inner wall, whereas the others were between UP and midline. **Results:** There was no significant difference between controls, PCD, and CRSwP. However, CF had 3 statistically different angles with controls, 5 with CRSwP, and 4 with PCD. Angle A average value was $126^\circ (\pm 16^\circ)$ in patients with CF, $138^\circ (\pm 19^\circ)$ in controls ($P = .007$), $145^\circ (\pm 15^\circ)$ in PCD ($P = .001$), and $138^\circ (\pm 14^\circ)$ in CRSwP ($P = .001$). Angle E average value was $35^\circ (\pm 10^\circ)$ in patients with CF, $20^\circ (\pm 6^\circ)$ in controls ($P < .001$), $21^\circ (\pm 4^\circ)$ in PCD ($P < .001$), and $22^\circ (\pm 6^\circ)$ in CRSwP ($P < .001$). **Conclusion:** Uncinate process's anatomy is only modified in CF: Angle between UP and inner wall of orbit is closed, and angles between UP and midline are opened. **Significance:** These measures quantify the medial bulging of lateral nasal wall and support nasofibrosopic observations.

Keywords

cystic fibrosis, CT scan, uncinat process, primary ciliary dyskinesia, chronic rhinosinusitis with polyps, lateral nasal wall

Introduction

Cystic fibrosis (CF) is the most common lethal autosomal recessive disorder in the Caucasian population affecting around 1/3000 children, with a carrier frequency of 1/25. It is a multi-system disorder where pulmonary and sinonasal involvements occur in 90% to 100% of patients, and up to 86% of children have nasal polyps.^{1–4} Patients with CF develop chronic rhinosinusitis (CRS) due to the defect in the CF transmembrane regulator (CFTR) protein. The membrane lining in the paranasal sinuses and the nose is identical to the membrane lining the lungs. As in lower airways (LAW), the defective CFTR protein results in viscous mucus.⁵ Consequently, mucociliary function is reduced, which facilitates bacterial colonization and infection thus leading to rhinosinusitis.^{6,7} In the past decades, infection of the LAW was the most prominent focus in treatment protocols for CF. Over the years, infection of the upper airways (UAW) gradually gained more attention in CF, as sinuses can be the reservoir of bacteria. Moreover, several studies showed concordance between organisms in UAW and LAW in patients with CF, suggesting that the UAW might influence the

patient's pulmonary status.^{8,9} Radiologic descriptions of rhinosinusitis in patients with CF were established by some authors: maxillary sinus pseudomucocele, median bulging of the lateral

¹ Ear Nose and Throat Department and Cystic Fibrosis Centre, Intercommunal Hospital of Créteil, Paris, France

² Pediatric Ear Nose and Throat Department, Robert Debré Pediatric Hospital, APHP, Paris, France

³ Radiology Department, Intercommunal Hospital of Créteil, France

⁴ Pediatric Department and Cystic Fibrosis Centre, Intercommunal Hospital of Créteil, Paris, France

⁵ Pneumology Department and Cystic Fibrosis Centre, Intercommunal Hospital of Créteil, Paris, France

⁶ Biostatistics Department, Henri Mondor Hospital, APHP, Créteil, France

⁷ University Paris Est Créteil, UPEC 94000 Créteil, France

⁸ DHU Ageing Thorax Vessel Blood, Créteil, France

Received December 28, 2018; revised January 13, 2019; accepted: January 14, 2019

Corresponding Author:

Rémi Hervochon, MD, MSc, 29 rue Miollis, 75015 Paris, France.
Email: remihervochon@gmail.com

nasal wall (LNW), nasal polyposis with bone erosion, and aplasia or hypoplasia of sphenoid and/or frontal sinuses.¹⁰ The median bulging of the LNW is a subjective concept. The LNW includes the uncinat process (UP), which is a vertical plate bone pendant to the ethmoid. To our knowledge, the deformation of UP has never been anatomically quantified.

The first purpose of this study was to objectify in patients with CF the median bulging of LNW by measuring the UP angulation. The second purpose was to compare these angulations with controls, CRS with nasal polyps (CRSwP, without CFTR gene mutations), and patients with primary ciliary dyskinesia (PCD).

Patients and Methods

Medical ethics committee of the French ENT Society approved this study; all adult patients and all legal representative of children gave their informed consent. All procedures performed in this study were in accordance with the ethical standards of the institutional and national research committee and with the 1964 Helsinki declaration and its later amendments or comparable ethical standards. In French legislation, a formal consent is not required for this type of study.

Thirty controls and 60 patients were included: 13 CRSwP, 17 PCD, and 30 CF recruited from the « Resources and competences Centres for cystic fibrosis » (French Cystic fibrosis Centre) of Intercommunal Hospital in Créteil and University Hospital Robert Debré in Paris. Computed tomography scan performed between April 2010 and April 2017, and medical records of all patients were analyzed. The exclusion criterion was a history of endonasal surgery (ethmoidectomy, maxillary antrostomy). Three-dimensional reconstructions on Advantage Windows Workstation were performed and both sides were examined. The UP is a plate bone pendant to the ethmoid, descending downwards and rearwards. Uncinate process is one element of the inner wall of the maxillary sinus. Each angle was measured by an otorhinolaryngologist and a radiologist who worked blinded with respect to the other and with respect to the group (controls, CRSwP, PCD, CF). The average of both observers' measurements was used for the statistical study.

The coronal plane was defined as perpendicular to the hard palate. In this plane, angle A was drawn between the orbit's medial wall and the UP; angle B between UP and the midline, opened upward; and angle C between UP and the midline, opened downward (Figure 1).

The axial plane was defined as parallel to the hard palate. In this plane, angle D was drawn between the UP and the midline, opened forward, and angle E was between UP and the midline, opened backward.

Given that the UP was measured 5 times, there was a chance of increasing the α risk. That is why a Bonferroni correction was performed, and an α risk of $0.05/5 = 0.01$ was tolerated. Data had a Gaussian distribution. A Student *t* test was used, with the null hypothesis of equal averages between 2 groups.

Results

Mean ages were 22 ± 12 , 52 ± 14 , 17 ± 16 , and 22 ± 14 years old for controls, CRSwP, PCD, and CF groups, respectively. Time required to measure both UP for each patient was 10 minutes. The inter-observer correlation coefficients were 0.56, 0.74, 0.63, 0.69, and 0.73 for A, B, C, D, and E, respectively. Angle A was smaller in CF than in PCD, CRSwP, and controls. There were statistically significant differences between patients with CF and the 3 other groups ($P < .01$; Tables 1 and 2, Figure 2). Angle B was greater in CF than in PCD, CRSwP, and controls. There were 2 statistically significant differences between CF and CRSwP and between CF and PCD ($P < .01$; Tables 1 and 2, Figure 2). Angle C was greater in CF than in PCD, CRSwP, and controls. There was a statistically significant difference between CF and CRSwP ($P = .0008$; Tables 1 and 2, Figure 2). Angle D was greater in CF than in PCD, CRSwP, and controls. There were statistically significant differences between patients with CF and the three other groups ($P < .01$; Tables 1 and 2, Figure 2). Angle E was greater in CF than in PCD, CRSwP, and controls. There were statistically significant differences between patients with CF and the 3 other groups ($P < .01$; Tables 1 and 2, Figure 2). For each of the 5 angles, there was no statistically significant difference between PCD, CRSwP, and controls ($P > .01$). In conclusion, CF had 4 statistically different angles with PCD, 5 with CRSwP, and 3 with controls (Table 2).

Discussion

Key Findings

In patients with CF, we have demonstrated that the angle between UP and the inner orbit wall (Angle A) is smaller when compared to other patients, whereas the angles between UP and midline (Angle D and E) are greater. Our results highlight statistically significant differences between CF, controls, PCD, and CRSwP. These 3 groups had comparable angle measurements.

Methodological Limitations and Strengths of the Study

Difficulty of measuring precisely each angle in a reproducible manner was compensated by the inclusion of a large number of measurements and patients, and the fact that they were measured bilaterally, and by 2 separate investigators. Finally, this measurement did not require a lot of time.

Comparison With Other Studies

Nasal and sinus disease is a key element in CF. Mainz et al showed that the presence of identical genotypes in UAW and LAW suggests that the UAW play a role as a reservoir of *Staphylococcus aureus* and *Pseudomonas aeruginosa* in CF.⁹ *Pseudomonas aeruginosa* positive UAW cultures precede positive LAW cultures in a substantial part of patients, suggesting some kind of cross infection between the UAW and LAW as explained in Hildes's study.⁸ Infection with *P. aeruginosa* plays

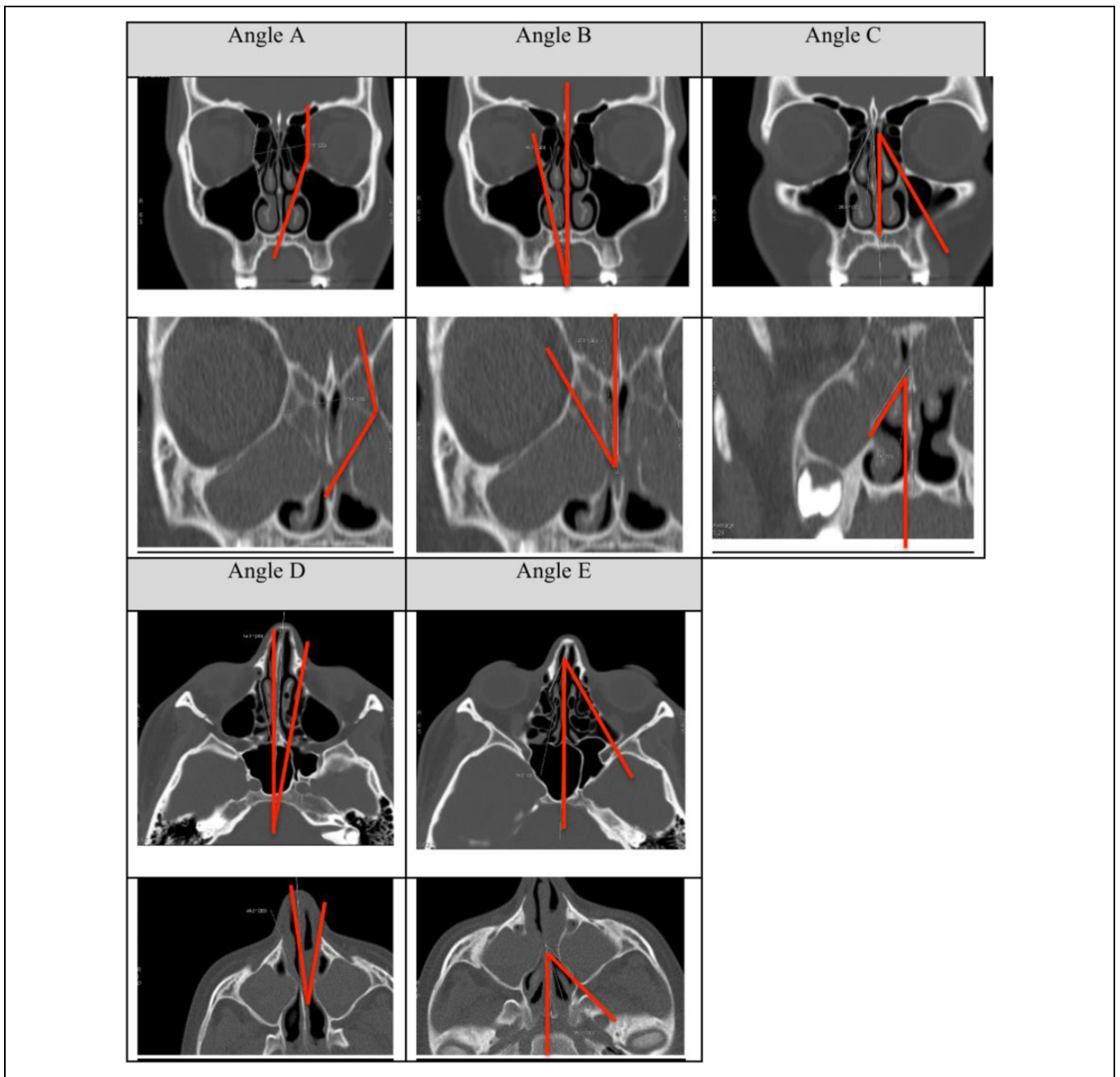


Figure 1. Different angles measured on axial sections in controls (top) and in cystic fibrosis (CF; bottom).

a crucial role in morbidity and mortality after lung transplantation in patients with CF.¹⁰ Less than 10% of patients with CF report sinonasal symptoms.⁴ One of the most common complaints is nasal obstruction, which is present in 32% to 81% of patients.^{1,4} But one-third of patients with a mean age of 3 years have nasal polyposis and 15% have a bulging of the LNW. A total of 25% of older patients have an isolated prominent UP.⁴ Brihaye et al. described clinical pattern of CF rhinosinusitis: mucopyosinusitis (pseudomucocele) of the maxillary antrum with bulging of the LNW, nasal polyposis with erosion of the LNW, and chronic purulent rhinosinusitis with an isolated

prominent UP.¹¹ On the other hand, all sinus CT scans in patients with CF reveal moderate to severe sinus disease.^{12,13}

These CT criteria have been perfectly described in Kang's literature review: The most prevalent findings reported were opacification of sinuses, frontal and sphenoidal aplasia or hypoplasia, underdevelopment of paranasal sinuses, and medial bulging of the LNW.¹⁴ The size of the maxillary sinus increases with advancing age in the control and chronic sinusitis patients but not in patients with CF.¹⁵ This is corroborated by Krzeski who suggests that more advanced pathological changes are found in CF than in CRS.¹⁶

Table 1. Average Angles Measurements in Each Group.

Groups	Angle A	Angle B	Angle C	Angle D	Angle E
CF	126° ± 16°	36° ± 13°	31° ± 12°	30° ± 10°	35° ± 10°
PCD	139° ± 15°	25° ± 11°	25° ± 9°	19° ± 6°	21° ± 4°
CRSwp	141° ± 14°	24° ± 9°	23° ± 7°	20° ± 6°	22° ± 7°
Controls	135° ± 19°	28° ± 13°	26° ± 6°	19° ± 7°	21° ± 6°

Abbreviations: CF, cystic fibrosis; CRSwp, chronic rhinosinusitis with polyps; PCD, primary ciliary dyskinesia.

Table 2. P Value of Each Student t Test.

Groups	Angle A	Angle B	Angle C	Angle D	Angle E
Controls-CF	.0077 ^a	.0388	.0116	<.0001 ^a	.0077 ^a
Controls-PCD	.2305	.1674	.4477	.7816	.2305
Controls-CRSwp	.1377	.0547	.0820	.2594	.1377
CF-PCD	.0003 ^a	.0012 ^a	.0111	<.0001 ^a	.0003 ^a
CF-CRSwp	.0002 ^a	.0003 ^a	.0008 ^a	<.0001 ^a	.0002 ^a
CRSwp-PCD	.7344	.5680	.4857	.4394	.7343

Abbreviations: CF, cystic fibrosis; CRSwp, chronic rhinosinusitis with polyps; PCD, primary ciliary dyskinesia.

^astatistically significant P Value.

According to Casserly, there is no significant difference between symptomatic and asymptomatic patients with CF with respect to their Lund–Kennedy endoscopic score or their Lund–Mackay CT score.¹³ Computed tomography is an excellent exam, but efforts should be made to minimize radiation exposure in patients with CF by limiting sinus CT scans to the preoperative context or for evaluation of potential sinusitis complications.¹²

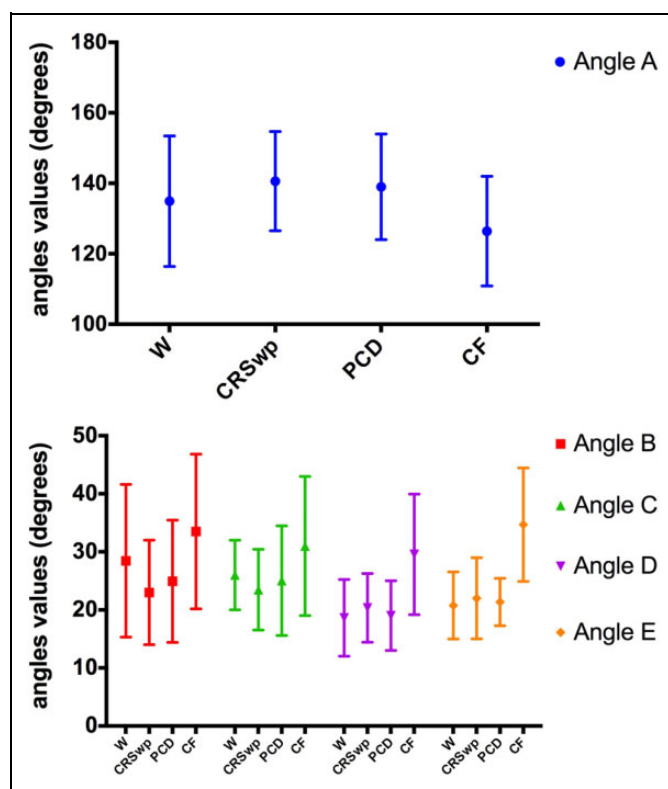
Clinical Applicability of the Study

Via CT measurements of UP angulation, we objectified and quantified the median bulging of the LNW in patients with CF. This supports nasofibrosopic observations.

The UP angle measurements also could be an argument for CF diagnosis for atypical patients. The US Cystic Fibrosis Foundation (Bethesda, Maryland) listed diagnostic criteria for CF: one or more of the phenotypic features of the disease with positive immunoreactive trypsin (a neonatal screening test), positive sweat test, a CF-causing mutation in each *CFTR* gene, or an abnormal nasal potential difference.¹⁷ The diagnosis of CF cannot be conclusive when the sweat test gives intermediate values, and the genetic analysis shows at most one CF causing mutation. These atypical patients usually present later in their lives with pancreatic failure and milder respiratory disease.

Nevertheless, a CT scan is not a valid criterion for sinus surgery in patients with CF.¹⁸ Indeed, the global analysis of the patient is necessary: symptoms and medical history, gram-negative bacillus presence, and endoscopic and radiological aspect.

For the first time, we described and quantified anatomical distortions of the UP in patients' with CF sinonasal cavities.

**Figure 2.** Average angles values of A, B, C, D, and E in each group.

These distortions are not found in PCD, CRSwp, and controls. Nevertheless, UP distortions are not 100% specific of CF. Indeed, allergic fungal sinusitis is a common diagnosis of LNW bulging. A review of the CT findings in allergic fungal sinusitis patients documents expansion of the sinuses in 43 of 45 patients studied.¹⁹

Authors' Note

This article was presented at IFOS (2017), in Paris, France.

Declaration of Conflicting Interests

The author(s) declared no potential conflicts of interest with respect to the research, authorship, and/or publication of this article.

Funding

The author(s) received no financial support for the research, authorship, and/or publication of this article.

ORCID iD

Rémi Hervochon, MD, MSc  <https://orcid.org/0000-0003-1569-3578>

References

- Coste A, Gilain L, Roger G, et al. Endoscopic and CT-scan evaluation of rhinosinusitis in cystic fibrosis. *Rhinology*. 1995;33(3): 152–156.
- Gysin C, Alothman GA, Papsin BC. Sinonasal disease in cystic fibrosis: clinical characteristics, diagnosis, and management. *Pediatr Pulmonol*. 2000;30(6):481–9.

3. Watelet JB, Van Cauwenberge P, Bachert C. Rhinological aspects of cystic fibrosis. *Monaldi Arch Chest Dis*. 2000;55(6):475–477.
4. Robertson JM, Friedman EM, Rubin BK. Nasal and sinus disease in cystic fibrosis. *Paediatr Respir Rev*. 2008;9(3):213–219.
5. Knowles MR, Robinson JM, Wood RE, et al. Ion composition of airway surface liquid of patients with cystic fibrosis as compared with normal and disease-control subjects. *J Clin Invest*. 1997;100(10):2588–2595.
6. Boucher RC. Human airway ion transport. Part one. *Am J Respir Crit Care Med*. 1994;150(1):271–281.
7. Regnis JA, Robinson M, Bailey DL, et al. Mucociliary clearance in patients with cystic fibrosis and in normal subjects. *Am J Respir Crit Care Med*. 1994;150(1):66–71.
8. Bonestroo HJ, de Winter-de Groot KM, van der Ent CK, Arets HG. Upper and lower airway cultures in children with cystic fibrosis: do not neglect the upper airways. *J Cyst Fibros*. 2010;9(2):130–134.
9. Mainz JG, Naehrlich L, Schien M, et al. Concordant genotype of upper and lower airways *P aeruginosa* and *S aureus* isolates in cystic fibrosis. *Thorax*. 2009;64(6):535–540.
10. Kang SH, Dalcin Pde T, Piltcher OB, Migliavacca Rde O. Chronic rhinosinusitis and nasal polyposis in cystic fibrosis: update on diagnosis and treatment *. *J Bras Pneumol*. 2015;41(1):65–76.
11. Brihaye P, Jorissen M, Clement PA. Chronic rhinosinusitis in cystic fibrosis (mucoviscidosis). *Acta Otorhinolaryngol Belg*. 1997;51(4):323–337.
12. Gergin O, Kawai K, MacDougall RD, et al. Sinus computed tomography imaging in pediatric cystic fibrosis: added value? *Otolaryngol Head Neck Surg*. 2016;155(1):160–165.
13. Casserly P, Harrison M, O'Connell O, et al. Nasal endoscopy and paranasal sinus computerised tomography (CT) findings in an Irish cystic fibrosis adult patient group. *Eur Arch Otorhinolaryngol*. 2015;272(11):3353–3359.
14. Kang SH, Piltcher OB, Dalcin Pde T. Sinonasal alterations in computed tomography scans in cystic fibrosis: a literature review of observational studies. *Int Forum Allergy Rhinol*. 2014;4(3):223–231.
15. Kim HJ, Friedman EM, Sulek M, et al. Paranasal sinus development in chronic sinusitis, cystic fibrosis, and normal comparison population: a computerized tomography correlation study. *Am J Rhinol*. 1997;11(4):275–281.
16. Krzeski A, Kapiszewska-Dzedzej D, Jakubczyk I, et al. Extent of pathological changes in the paranasal sinuses of patients with cystic fibrosis: CT analysis. *Am J Rhinol*. 2001;15(3):207–210.
17. Farrell PM, Rosenstein BJ, White TB, et al; Cystic Fibrosis Foundation. Guidelines for diagnosis of cystic fibrosis in newborns through older adults: Cystic Fibrosis Foundation consensus report. *J Pediatr*. 2008;153(2):S4–S14
18. Rasmussen J, Aanaes K, Norling T, et al. CT of the paranasal sinuses is not a valid indicator for sinus surgery in CF patients. *J Cyst Fibros*. 2012;11(2):92–99.
19. Mukherji SK, Figueroa RE, Ginsberg LE, et al. Allergic fungal sinusitis: CT findings. *Radiology*. 1998;207(2):417–422.