



HAL
open science

Response to systemic therapy in fumarate hydratase-deficient renal cell carcinoma

Lucia Carril-Ajuria, Emeline Colomba, Luigi Cerbone, Carmen Romero-Ferreiro, Laurence Crouzet, Brigitte Laguerre, Constance Thibault, Cécile Vicier, Guillermo de Velasco, Aude Fléchon, et al.

► To cite this version:

Lucia Carril-Ajuria, Emeline Colomba, Luigi Cerbone, Carmen Romero-Ferreiro, Laurence Crouzet, et al.. Response to systemic therapy in fumarate hydratase-deficient renal cell carcinoma. *European Journal of Cancer*, 2021, 151, pp.106-114. 10.1016/j.ejca.2021.04.009 . hal-04242389

HAL Id: hal-04242389

<https://hal.u-pec.fr/hal-04242389>

Submitted on 22 Jul 2024

HAL is a multi-disciplinary open access archive for the deposit and dissemination of scientific research documents, whether they are published or not. The documents may come from teaching and research institutions in France or abroad, or from public or private research centers.

L'archive ouverte pluridisciplinaire **HAL**, est destinée au dépôt et à la diffusion de documents scientifiques de niveau recherche, publiés ou non, émanant des établissements d'enseignement et de recherche français ou étrangers, des laboratoires publics ou privés.



Distributed under a Creative Commons Attribution - NonCommercial 4.0 International License

Response to systemic therapy in Fumarate hydratase deficient Renal cell carcinoma

Authors: Lucia Carril-Ajuria^{1,2}, Emeline Colomba¹, Luigi Cerbone¹, Carmen Romero-Ferreiro³, Laurence Crouzet⁴, Brigitte Laguerre⁴, Constance Thibault⁵, Cécile Vicier⁶, Guillermo de Velasco², Aude Fléchon⁷, Carolina Saldana⁸, Patrick R. Benusiglio⁹, Brigitte Bressac-de Paillerets¹⁰, Marine Guillaud-Bataille^{9,10}, Pauline Gaignard¹¹, Jean-Yves Scoazec¹², Stéphane Richard^{13,14}, Olivier Caron¹⁵, Bernard Escudier^{1,13} and Laurence Albiges^{1,13*}.

Affiliations:

1. Department of Medical Oncology, Gustave Roussy, Villejuif, France.
2. Department of Medical Oncology, University Hospital 12 de Octubre, Madrid, Spain.
3. CIBERESP, Instituto i+12, University Hospital 12 de Octubre, Madrid, Spain.
4. Department of Medical Oncology, Centre Eugene Marquis, Rennes, France.
5. Department of Medical Oncology, Hôpital Européen Georges-Pompidou, Paris, France.
6. Department of Medical Oncology, Institute Paoli-Calmettes, Marseille, France.
7. Department of Medical Oncology, Centre Léon-Bérard, Lyon, France.
8. Department of Medical Oncology, Hôpital Henri Mondor Créteil AP-HP, France.
9. UF d'Oncogénétique, Département de Génétique et Institut Universitaire de Cancérologie, GH Pitié-Salpêtrière, AP-HP. Sorbonne Université, F-75013 Paris.
10. Service de Génétique, Molecular Genetic Department, GRCC, 94805 Villejuif, France.
11. Biochemistry Department, Hôpital Bicêtre, APHP Université Paris-Saclay, Le Kremlin Bicêtre F-94275, France.
12. Department of Pathology, University Paris-Saclay, Gustave Roussy Cancer Center, Villejuif, France.
13. Réseau National de Référence pour Cancers Rares de l'Adulte PREDIR labellisé par l'INCa, Hôpital Bicêtre, AP-HP, Le Kremlin-Bicêtre, France.
14. Génétique Oncologique EPHE, PSL Research University, Paris, and UMR9019 CNRS Genome Integrity and Cancers, Institute Gustave Roussy, Villejuif, France.

15. Laboratory Integrative Tumor Immunology and Genetic Oncology, Institute Gustave Roussy, Villejuif, France.

*Corresponding author:

Laurence ALBIGES, Gustave Roussy, Université Paris-Saclay, Département de médecine Oncologique, Villejuif, F-94805, France. Fax : 01 42 11 53 05. E-mail address: laurence.albiges@gustaveroussy.fr (L. Albiges).

Keywords: Hereditary leiomyomatosis; non-clear cell RCC; FH-deficient RCC; antiangiogenics; immunotherapy.

The authors declare no potential conflicts of interest.

Abstract: 249

Manuscript: 2835

Tables: 4

Figures: 1

Supplementary:

- 4 tables

- 1 figure

References: 33

Abstract

Purpose

Fumarate hydratase deficient (FHdef) renal cell carcinoma (RCC) is a rare entity associated with the hereditary leiomyomatosis and RCC syndrome with no standard therapy approved. The aim of this retrospective study is to evaluate the efficacy of different systemic treatments in this population.

Methods

We performed a multicenter retrospective analysis of Fhdef RCC patients to determine the response to systemic treatments. The endpoints were objective response rate (ORR), time-to-treatment failure (TTF) and overall survival (OS). The two latter were estimated using the Kaplan-Meier method.

Results

Twenty-four Fhdef RCC patients were identified and 21 under systemic therapy were included in the analysis: 10 received cabozantinib, 14 sunitinib, 9 “other antiangiogenics” (sorafenib, pazopanib, axitinib), 3 erlotinib-bevacizumab, 3 mTOR inhibitors and 11 immune checkpoint blockers (ICB). ORR for treatments were respectively: 50% for cabozantinib, 43% for sunitinib, 63% for “other antiangiogenics”, 30% for E-B, whereas ORR was 0% for mTOR inhibitors and 18% for ICB. Median TTF was significantly higher with antiangiogenics (11.6 months) than with mTOR-inhibitors (4.4 months) or ICB (2.7 months). In first line setting antiangiogenics presented a higher ORR compared to nivolumab-ipilimumab (64% vs 25%) and a significantly superior mTTF (11.0 months vs 2.5 months; $p=0.0027$). Median OS from start of first systemic treatment was 44.0 months (95%CI: 13.0-95.0).

Conclusions

We report the first European retrospective study of Fhdef RCC patients treated with systemic therapy with a remarkably long median OS of 44.0 months. Our results suggest that antiangiogenics may be superior to ICB/mTOR inhibitors in this population.

Introduction

Fumarate hydratase-deficient renal cell carcinoma (Fhdef RCC) is a rare subtype of RCC associated with the hereditary leiomyomatosis and renal cell cancer (HLRCC) syndrome. This syndrome is a rare autosomal dominant disease related to *FH* gene germline loss of function mutations that confers an increased risk of developing uterine and cutaneous leiomyomas, and RCC [1,2]. The lifetime-risk of developing RCC for HLRCC patients is around 19-32%, however due to its rarity the worldwide incidence is unknown [1,3]. This type of RCC is typically diagnosed at a young age (\approx 40 years) [3,4]. As the *FH* gene is a tumor suppressor, loss of function occurs in two-hits, leading to loss of FH protein expression and increase of 2-succinocysteine [2SC] in tumors. Fhdef tumors can therefore be identified by immunohistochemistry (IHC) with FH and 2SC staining (FH negative, 2SC positive) [5]. Some tumors display loss of FH expression in the absence of an identified germline mutation. These cases constitute a different entity that can be due to either an unidentified cryptic germline mutation or two somatic events [2,6]. Fhdef RCC includes both the hereditary and sporadic forms.

From a morphological perspective, Fhdef RCC used to be described as a type-2 papillary RCC (pRCC), however it can present as different histological subtypes [5]. The *FH* gene is located at 1q42.3-q43 and encodes a Krebs's cycle enzyme catalyzing the formation of L-malate from fumarate [7,8]. Fhdef tumors are associated with increased intracellular fumarate leading to accumulation of the hypoxia inducible factor (HIF α) which upregulates the expression of angiogenic genes [1]. In addition, increased fumarate levels induce a metabolic shift to aerobic glycolysis [1]. In contrast to other inherited RCC susceptibility syndromes, HLRCC-associated kidney tumors are usually solitary, unilateral and have an aggressive behavior, with around 80% being metastatic at diagnosis[3].

The treatment landscape of metastatic RCC has improved greatly during the last 20 years with a median overall survival (mOS) exceeding 30 months with immune checkpoint blockade (ICB) combinations and antiangiogenics (AA)-ICB combinations [9,10]. However, pivotal trials have only enrolled ccRCC patients. Moreover, prospective trials in nccRCC used to mix these patients as a single entity, whereas biological and clinical data have demonstrated that each subtype is a singular disease. Few trials have focussed on pRCC patients. Drugs as everolimus, sunitinib, axitinib,

foretinib, crizotinib and savolitinib have been investigated, with response rates (RR) below 15%, except for axitinib (RR 35.7% in the type-2 pRCC cohort of the AXIPAP trial) [11–18]. Recently, the phase II PAPMET trial demonstrated the superiority of cabozantinib versus sunitinib in terms of both objective response rate (ORR) (23% vs 4%) and median progression free survival (mPFS) (9.0 vs 5.6 months) in pRCC patients [19].

FHdef RCC is a particular nccRCC with no standard therapy approved. To date there is only one trial with reported results in this rare population, the AVATAR trial. This phase II trial showed promising results of the erlotinib-bevacizumab (E-B) combination, especially in the HLRCC-associated RCC group. The HLRCC-associated RCC group presented a 72% ORR and a 21.1 months mPFS compared to a 35% ORR and a 8.8 months mPFS in the sporadic pRCC cohort [4].

Given the lack of evidence on the efficacy of systemic therapies in this population, we conducted a multicenter retrospective study in advanced FH-deficient RCC under systemic therapy to help treatment decision-making.

Methods

Study design and population

In February 2020, we performed a collaborative multicenter retrospective review of all metastatic FHdef RCC patients treated within the French Genito Urinary Group (Groupe d'Etude des Tumeurs Urogenitales (GETUG)) and the University Hospital 12 de Octubre. FHdef RCC patients were defined as patients with high grade or type-2 pRCC tumors and immunohistochemical confirmation of FH deficiency (defined as FH negative and/or 2SC positive) or *FH* germline mutation [5]. When available, FH enzymatic activity was measured by spectrophotometric-analysis in blood lymphocytes [20]. Central pathological review was performed by CARARE (Cancer Rares du Rein) for France and at University Hospital 12 de Octubre for Spain. Eligibility criteria included adult patients with measurable disease by the Response Evaluation Criteria of Solid Tumors (RECIST) receiving systemic treatment for advanced Fhdef RCC. Standardized chart review collected date of diagnosis, age at diagnosis, gender, date of nephrectomy, date of first metastasis, type of metastatic site at initiation of systemic

treatment, and prognostic factors according to the International Metastatic RCC Database Consortium (IMDC) risk model. All patients had regular CT-scanner evaluation based on local practice. The response by RECIST was determined locally.

Statistical analyses

The patient's characteristics (sex, age at diagnosis, Karnofsky Performance Scale (KPS), site of metastases, IMDC risk group, prior nephrectomy, grade, number of lines and type of systemic therapy were described (median and interquartile range [IQR] for continuous variables and absolute and relative frequencies for categorical variables) for the global population and for the different treatment groups. Median follow-up from the date of first-line therapy was estimated using the reverse Kaplan-Meier (KM) method. Patients' characteristics and the different types and lines of systemic treatment were reported. Different systemic treatments were classified into six groups: ICB, including nivolumab-ipilimumab or nivolumab or other anti-PD1/PD-L1 study drugs, cabozantinib, sunitinib, E-B, mTOR inhibitors and "other AA". Patients treated with pazopanib, axitinib or sorafenib were included in the group "other AA". The endpoints were ORR, time to treatment failure (TTF) and OS. Best response was determined by local assessment every 8-12 weeks according to RECIST 1.1 criteria as partial response (PR), complete response (CR), stable disease (SD) and progressive disease (PD). Objective response rate was defined as CR+PR and disease control rate (DCR) as CR+PR+SD. DCR and ORR were compared between the different treatment groups using the Fisher's exact test. The TTF was defined as the time from the start of therapy to the discontinuation of treatment for any reason, including disease progression, toxicity and death. Patients with no treatment failure were censored at the date of last follow-up. These two time-to-events were estimated by using KM method and the median with its 95% confidence interval (CI) was reported. We compared TTF and OS at first line according to the IMDC prognostic groups (log-rank test) and according to type of systemic treatment (stratified log-rank test). For the latter, no interpretation can be performed based on the KM estimation considering the observational design. The cut-off date for the analysis was May 25, 2020. The statistical analyses were performed with SAS software 9.4 (SAS Institute).

Results

Patient's and tumors characteristics

We identified 24 Fhdef RCC patients from 7 centers in two countries (France and Spain). Twenty-one patients had received systemic treatment for metastatic disease and were included in the analysis. Patients had been diagnosed from January 2005 to January 2019. Patient and tumor characteristics are described in Table 1. A list of the germline mutations identified, the FH enzymatic activity measured in patient's bloods and the FH/2SC staining can be found in the supplementary Table 2. The systemic treatments are reported in Table 2. Half of patients (47.6%) were metastatic at diagnosis. All patients except one, received at least one line of AA treatment (95.2%, n=20). Three (14.3%) patients received mTOR-inhibitors and 3 (14.3%) patients received erlotinib-bevacizumab, and 11 (52.4%) patients received ICB. Regarding ICB therapy, four (19%) patients received upfront nivolumab-ipilimumab (nivo-ipi), while the rest of ICB treatments, including nivolumab (n=4) or anti-PD1/PD-L1 study drugs (n=3) were given in second or posterior therapy lines. Median age at diagnosis was 37.7 (IQR: 20.0-61.0) years with similar frequencies of men and women, in 47.6% and 52.4% respectively. Most patients had nephrectomy (71.4%). Median time from diagnosis to metastasis was 7.0 months (95% CI:0.0-18.0) and median time from metastasis to first-line treatment was 2.0 months (95% CI:1.0-3.0). In this cohort, abdominal lymph nodes and lung nodes were the most common site of metastases (Table 1). The IMDC risk groups were favorable, intermediate and poor; in 33.3% (n=6), 50.0% (n=9) and 16.7% (n=3) of patients respectively. Nine patients (42.8%) received ≥ 3 lines of systemic treatment.

Table 1. Baseline patients' characteristics

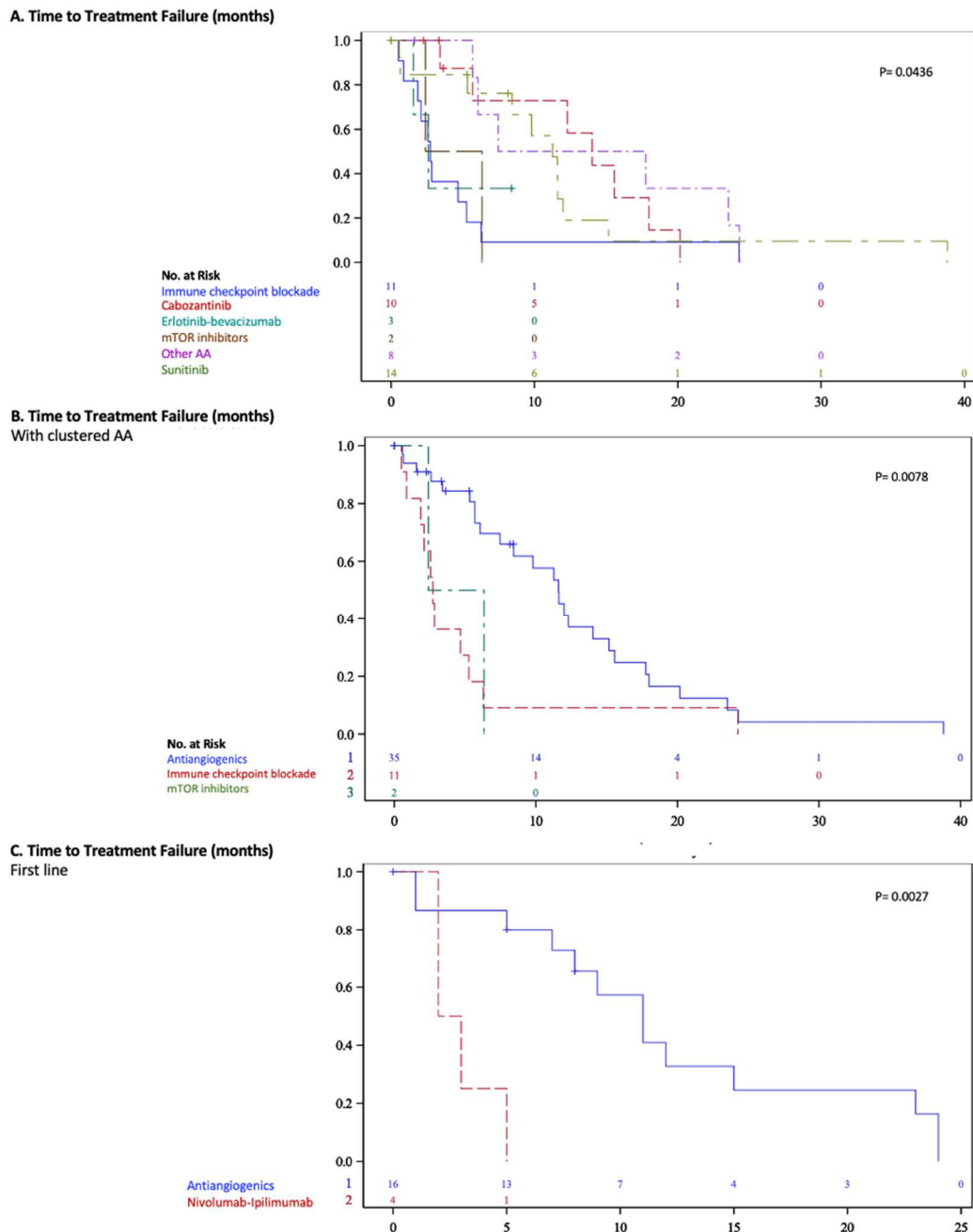
Characteristics	All patients (n=21) N (%)
Age at diagnosis (years) median IQR	37.7 (20.0-61.0)
Sex	
Male	10 (47.6)
Female	11 (52.4)
Country	
France	20 (95.2)
Spain	1 (4.8)
Cutaneous leiomyomas	
Yes	4 (19.0)
No	17 (80.9)
Uterine leiomyomas	
Yes	7 (33.3)
No	14 (66.7)
FH mut	
Molecular diagnosis	16 (76.2)
Immunohistochemistry	2 (9.5)
Both	3 (14.3)
Germline mutation	
Yes	19 (90.5)
No	1 (4.8)
Not analysed	1 (4.8)
Metastatic at diagnosis	
Yes	10 (47.6)
No	11 (52.4)
KPS at start of 1st line	
≥ 80%	16 (76.2)
<80%	5 (23.8)
Location of metastases	
Lung	8 (38.1)
Bone	7 (33.3)
Liver	6 (28.6)
Brain	0 (0.0)
Lymph nodes	
Abdominal	6 (28.6)
Supradiaphragmatic	2 (9.5)
Both	4 (19.0)
IMDC risk group at 1st line	
Favorable	6 (28.6)
Intermediate	9 (42.9)
Poor	3 (14.3)
Missing	3 (14.3)
Prior nephrectomy	
Yes	15 (71.4)
No	4 (19.0)
Missing	2 (9.5)
Grade	
I	1 (4.8)
II	1 (4.8)
III	5 (23.8)
IV	5 (23.8)
Missing	9 (42.9)

IMDC: International Metastatic Renal Cell Carcinoma Database Consortium, IQR: Interquartile range.

Median time to treatment failure and median overall survival in all population

Median TTF (mTTF) under AA was 11.6 months (95% CI: 6.1-15.2) (Figure 1B). More specifically, mTTF was 14.0 months (95% CI: 3.4-18), 11.6 months (95% CI: 0.6-12.0), 17.7 months (95% CI: 5.7-24.3), 5.5 months, for cabozantinib, sunitinib, “other AA” and erlotinib-bevacizumab, respectively (Figure 1A). Median TTF was significantly shorter in patients treated with either mTOR-inhibitors (4.4 months (95% CI: 2.4-6.3) or ICB (2.7 months (95% CI: 0.9-5.3) compared to those treated with AA (11.6 months) ($p=0.0078$) (Figure 1B). No significant differences in TTF were observed between frontline nivo-ipi and nivolumab (or anti-PD1/PD-L1 study drugs) in second or subsequent therapy lines ($p=0.6039$). Moreover, AA presented a significantly superior mTTF (11.0 months (95% CI: 5.0-15.0)) than nivo-ipi (2.5 months (95% CI: 2.0-5.0)) in first line setting ($p=0.0027$) (Figure 1C). First line mTTF was 11.5 months (95% CI: 2.0-24.0 months), 5.0 months (95% CI: 1.0-15.0), and 3.0 months (95% CI: 1.0-7.0) in the favourable, intermediate and poor risk groups, respectively ($p=0.079$) (Supplementary Figure 1).

Figure 1. Unadjusted Kaplan-meier for median time-to-treatment failure (mTTF) for the different treatment groups: A) All treatment groups. B) All antiangiogenics clustered into one group. C) Only first-line setting: nivolumab-ipilimumab versus antiangiogenics clustered into one group.



After a median follow-up of 32.0 months (95%IC:7.0-51.0) at the time of analysis, 10 (47.6%) patients had died from disease. Median OS from time of first treatment

initiation was 44.0 months (95%CI:13.0-95.0). Median OS according to IMDC risk group in first line setting was 69.5 months (95% CI: 25.0-95.0) and 35.0 months (12.0-41.0 months) in the favourable and intermediate risk groups. The poor risk group was not evaluable for OS due the lack of events.

Response rate according to systemic therapy

Antiangiogenics

The ORR was 50%, 43%, 63% and 30%, in patients treated with cabozantinib, sunitinib, “other AA” and erlotinib-bevacizumab, respectively (Table 2). Antiangiogenics presented higher ORR (64%) than nivo-ipi (25%) in first line setting (p=0.622) (Table 4).

Immune checkpoint blockers

The ORR and DCR were 18% and 36%, respectively (Tables 2 and 3). The ORR with ICB tended to be inferior compared to AA (p=0.071). First line nivo-ipi compared to anti-PD-1/PD-L1 agents in second or subsequent lines presented a 25% ORR and a 14% ORR, respectively (Supplementary Table 1).

mTOR-inhibitors

No responses were seen in patients treated with mTOR-inhibitors (Tables 2 and 3).

Table 2. Response rates according to systemic therapy (including by type of antiangiogenic).

Systemic therapy	N	Line of therapy 1L%/>1L%	CR	PR	SD	PD	Missing **	ORR %	P-value	DCR %	P-value
Immune checkpoint blockers	11	36/64	1 (9)	1 (9)	2 (18)	7 (63)	0	18	0.266	36	0.314
Cabozantinib	10	0/100	0 (0)	5 (50)	3 (30)	1 (10)	1	50		80	
Sunitinib	14	93/7	1 (7)	5 (36)	2 (14)	3 (21)	3	43		57	
Others AA* (pazopanib, axitinib, sorafenib)	8	38/62	0 (0)	5 (63)	1 (13)	0 (0)	2	63		76	
mTOR inhibitors	3	0/100	0 (0)	0 (0)	1 (30)	1 (30)	1	0		30	
Erlotinib-bevacizumab	3	0/100	0 (0)	1 (30)	1 (30)	1 (30)	0	30		60	

* AA: antiangiogenics. ** Missing data for evaluation of best response according to RECIST 1.1. N: population. ORR: overall response rate. DCR: disease control rate. PR: partial response. CR: complete response. SD: stable disease. PD: progressive disease. mTOR: mammalian target of rapamycin. 1L: first line.

Table 3. Response rates according to type of systemic therapy.

Systemic therapy	N	Line of therapy 1L% / >1L%	CR	PR	SD	PD	Missing **	ORR %	P-value	DCR %	P-value
Immune checkpoint blockers	11	36/64	1(9)	1(9)	2(18)	7(63)	0	18	0.071	36	0.106
Antiangiogenics	35	46/54	1(3)	16(46)	7(20)	5(14)	7	49		69	
mTOR inhibitors	3	0/100	0(0)	0(0)	1(30)	1(30)	1	0		30	

** Missing data for evaluation of best response according to RECIST 1.1. N: population. ORR: overall response rate. DCR: disease control rate. PR: partial response. CR: complete response. SD: stable disease. PD: progressive disease. mTOR: mammalian target of rapamycin. 1L: first line.

Table 4. Response rates in first line setting according to systemic therapy.

Systemic therapy	N	CR	PR	SD	PD	ORR %	P-value	DCR %	P-value
Nivolumab-Ipilimumab	4	1(25)	0(0)	1(25)	2(50)	25	0.409	50	0.622
Antiangiogenics	14*	1(7)	8(58)	2(14)	3(21)	64		79	

*Three patients treated with frontline antiangiogenics had missing data for evaluation of best response according to RECIST 1.1. N: population. ORR: overall response rate. DCR: disease control rate. PR: partial response. CR: complete response. SD: stable disease. PD: progressive disease

Discussion

FHdef RCC is a rare and aggressive disease with no standard therapy approved. To date there is only one phase II trial with reported results in this population. This study assessed the efficacy of erlotinib-bevacizumab showing encouraging results with a 72% ORR in the HLRCC-associated RCC compared to 35% in the sporadic pRCC group [4]. Recently, Gleeson et al. reported the results of an American retrospective study evaluating the response to systemic therapy in FHdef RCC (n=26) [21]. The VEGF/mTOR combinations presented the highest ORR (44%) followed by AA monotherapy (ORR 20%) while no responses were seen with ICB or mTOR monotherapy (Supplementary Table 3) [21].

In this context, we report a cohort of 21 metastatic Fhdef RCC patients under systemic therapy. Antiangiogenics, showed stronger antitumor activity (49%) than ICB

(18%) and mTOR-inhibitors (0% ORR), consistent with previous results [21]. Antiangiogenics presented the longest mTTF, 11.6 months, compared to 2.7 and 4.4 months in the ICB and mTOR groups, respectively ($p=0.0078$). Antiangiogenics were also superior to nivo-ipi in first line setting (ORR: 64% vs 25%; mTTF: 11.0 vs 2.5 months). Among all AA, the group of “other AA” and cabozantinib were associated with the highest ORRs, 63% and 50% respectively, and were also superior in terms of mTTF, 17.7 and 14.0 months, respectively. Of note, these agents had predominately been given in a pretreated setting in contrast to sunitinib that had been mostly given in first line (Table 2). Recent studies reported the activity of *MET*-inhibitors in pRCC, including type-2 pRCC [13–15,19]. Although according to the TCGA *MET* alterations are not associated to FH deficient tumors, it is unclear whether the *FH* status has been evaluated in the PAPMET trial, and thus according to the results of this trial, cabozantinib could be of value in this population [19,22]. Interestingly, the 50% ORR observed with cabozantinib in our cohort exceeds previous reported results, including those observed in the PAPMET trial (23%) and from other retrospective studies [19,23,24]. These results contrast particularly with those observed in the American FHdef RCC cohort where no responses were seen with cabozantinib [21].

The HLRCC-associated RCC carcinogenesis is characterized by the upregulation of the HIF-VEGF pathway and the shift to aerobic glycolysis [1]. Accordingly, the combination of erlotinib and bevacizumab, which has been shown to revert the Warburg effect, was investigated in the AVATAR trial [25,26]. This phase II study investigated the efficacy and safety of erlotinib-bevacizumab in 83 HLRCC-associated RCC and sporadic pRCC patients showing encouraging results. The HLRCC-associated RCC group presented a 72% ORR and a mPFS of 21.1 months, compared to the 35% ORR and the 8.8 months mPFS observed in the sporadic cohort [25]. However, the trial took ten years to complete accrual, which could imply a selection bias. A small Korean retrospective study evaluated the role of erlotinib-bevacizumab in FHdef RCC ($n=10$). The ORR was 50%, however the mPFS was shorter (13.3 months) than in the AVATAR trial [27]. According to the results of the AVATAR trial, erlotinib-bevacizumab is currently recommended by the NCCN guidelines for advanced HLRCC patients [28]. In our cohort the mTTF under E-B was 5.5 months, shorter than in the AVATAR trial (21.1 months) and in the Korean cohort (13.3 months), however the

number of patients in our cohort (n=3) was small and they had been exposed to up to four prior therapy lines. [25,27].

The mOS in our cohort was surprisingly long, 44.0 months. This could be explained by a long-term survivor (95 months) and an heterogeneous and heavily pretreated population. Indeed, in our cohort half of the patients received ≥ 3 lines of systemic therapy and 52% of patients presented an OS superior to two years with a mFU of 32 months.

As nccRCC, FHdef RCC patients have generally been excluded from prospective trials because of their rareness. Recently, several phase II trials have been designed to address specific nccRCC subtypes such as the pRCC [12–15,18]. Foretinib, a multikinase-inhibitor (*MET*, *RON*, *AXL*, *TIE-2* and *VEGF*) was investigated for pRCC in a phase II trial, showing a 13.5% ORR which increased up to 50% in *MET* germline mutation carriers [13]. Savolitinib, a *MET*-inhibitor, was also investigated in pRCC [15]. The results were promising in the *MET*-driven cohort with an ORR and mPFS of 18% and 6.2 months respectively, compared to the *MET*-independent cohort (ORR: 0%, mPFS: 1.4 months). Unfortunately, the phase III trial closed early due to slow accrual [17].

Further understanding of the molecular biology of pRCC paved the way to design biomarker-driven trials. Crizotinib showed encouraging activity in *MET*-mutated type-1 pRCC with a 50% ORR and a PFS at 2-years of 80%, compared to 6% and 22% in the non-mutated group, respectively [14]. According to these results, the phase II PAMMET trial was conducted to evaluate the efficacy of different *MET*-inhibitors compared to sunitinib in pRCC, including both type-1 and type-2 pRCC [19]. Interestingly, cabozantinib demonstrated a significant improvement in both ORR and PFS compared to sunitinib and other two *MET*-inhibitors [19]. Cabozantinib presented an ORR of 23% while sunitinib, savolitinib and crizotinib, presented a 4%, 3%, 0% ORR, respectively. Median PFS was also superior with cabozantinib (9 months), compared to sunitinib (5.6 months), savolitinib (3 months) and crizotinib (2.8 months) [19].

Some single-arm trials have investigated approved targeted therapies for ccRCC in pRCC suggesting the superiority of AA over mTOR-inhibitors (Supplementary

Table 4) [11,12]. Particularly, axitinib showed encouraging antitumor activity in type-2 pRCC with a 35.7% ORR compared to 7.7% in type-1 pRCC [18]. However, the trials size or their methodology prevent from drawing strong conclusions on the efficacy. Immunotherapy has also been investigated in metastatic pRCC with interesting results [16,29,30]. Furthermore, frontline nivo-ipi is currently been investigated in nccRCC in the randomized phase II trial SUNNIFORECAST [31].

Our work is not without limitations inherent to its retrospective nature. Also, given the small sample size and that we compared treatments regardless treatment line, results should be interpreted with caution; no multivariable analyses were performed. Moreover, the lack of central radiological review may lead to some biases.

Conclusion

We report the first European retrospective cohort of metastatic Fhdef RCC under systemic therapy (n=21). Fhdef RCC is a rare and aggressive disease which occurs at an uncommon younger age. The mOS in our cohort was surprisingly long, 44.0 months, suggesting the benefit of new drugs in this population. Our results suggest the superiority of AA over ICB and mTOR-inhibitors in FHdef RCC. Antiangiogenics were also superior to nivo-ipi in first line setting. Due to the limited sample size, it is not possible to especially recommend one antiangiogenic over another. Further prospective studies based on the molecular biology of this tumor and global collaborations including larger number of patients are required to improve the understanding of this rare disease and help treatment decision-making.

Declaration of Interest statement

Declaration of Interest statement has been attached as a separate file.

References

- [1] Linehan WM, Rouault TA. Molecular pathways: Fumarate hydratase-deficient kidney cancer--targeting the Warburg effect in cancer. *Clin Cancer Res Off J Am Assoc Cancer Res* 2013;19:3345–52. <https://doi.org/10.1158/1078-0432.CCR-13-0304>.
- [2] Lau HD, Chan E, Fan AC, Kunder CA, Williamson SR, Zhou M, et al. A Clinicopathologic and Molecular Analysis of Fumarate Hydratase-deficient Renal Cell Carcinoma in 32 Patients. *Am J Surg Pathol* 2020;44:98–110. <https://doi.org/10.1097/PAS.0000000000001372>.
- [3] Muller M, Ferlicot S, Guillaud-Bataille M, Le Teuff G, Genestie C, Deveaux S, et al. Reassessing the clinical spectrum associated with hereditary leiomyomatosis and renal cell carcinoma syndrome in French *FH* mutation carriers: MULLER et al. *Clin Genet* 2017;92:606–15. <https://doi.org/10.1111/cge.13014>.
- [4] Srinivasan R, Gurram S, Al Harthy M, Singer EA, Sidana A, Shuch BM, et al. Results from a phase II study of bevacizumab and erlotinib in subjects with advanced hereditary leiomyomatosis and renal cell cancer (HLRCC) or sporadic papillary renal cell cancer. *J Clin Oncol* 2020;38:5004–5004. https://doi.org/10.1200/JCO.2020.38.15_suppl.5004.
- [5] Muller M, Guillaud-Bataille M, Salleron J, Genestie C, Deveaux S, Slama A, et al. Pattern multiplicity and fumarate hydratase (FH)/S-(2-succino)-cysteine (2SC) staining but not eosinophilic nucleoli with perinucleolar halos differentiate hereditary leiomyomatosis and renal cell carcinoma-associated renal cell carcinomas from kidney tumors without FH gene alteration. *Mod Pathol Off J U S Can Acad Pathol Inc* 2018;31:974–83. <https://doi.org/10.1038/s41379-018-0017-7>.
- [6] Pan X, Zhang M, Yao J, Zeng H, Nie L, Gong J, et al. Fumaratehydratase-deficient renal cell carcinoma: a clinicopathological and molecular study of 13 cases. *J Clin Pathol* 2019;72:748–54. <https://doi.org/10.1136/jclinpath-2019-205924>.
- [7] Menko FH, Maher ER, Schmidt LS, Middleton LA, Aittomäki K, Tomlinson I, et al. Hereditary leiomyomatosis and renal cell cancer (HLRCC): renal cancer risk, surveillance and treatment. *Fam Cancer* 2014;13:637–44. <https://doi.org/10.1007/s10689-014-9735-2>.
- [8] The Multiple Leiomyoma Consortium. Germline mutations in FH predispose to dominantly inherited uterine fibroids, skin leiomyomata and papillary renal cell cancer. *Nat Genet* 2002;30:406–10. <https://doi.org/10.1038/ng849>.
- [9] Motzer RJ, Tannir NM, McDermott DF, Arén Frontera O, Melichar B, Choueiri TK, et al. Nivolumab plus Ipilimumab versus Sunitinib in Advanced Renal-Cell Carcinoma. *N Engl J Med* 2018;378:1277–90. <https://doi.org/10.1056/NEJMoa1712126>.
- [10] Rini BI, Plimack ER, Stus V, Gafanov R, Hawkins R, Nosov D, et al. Pembrolizumab plus Axitinib versus Sunitinib for Advanced Renal-Cell Carcinoma. *N Engl J Med* 2019;380:1116–27. <https://doi.org/10.1056/NEJMoa1816714>.
- [11] Ravaud A, Oudard S, De Fromont M, Chevreau C, Gravis G, Zanetta S, et al. First-line treatment with sunitinib for type 1 and type 2 locally advanced or metastatic

- papillary renal cell carcinoma: a phase II study (SUPAP) by the French Genitourinary Group (GETUG). *Ann Oncol* 2015;26:1123–8. <https://doi.org/10.1093/annonc/mdv149>.
- [12] Escudier B, Molinie V, Bracarda S, Maroto P, Szczylik C, Nathan P, et al. Open-label phase 2 trial of first-line everolimus monotherapy in patients with papillary metastatic renal cell carcinoma: RAPTOR final analysis. *Eur J Cancer* 2016;69:226–35. <https://doi.org/10.1016/j.ejca.2016.08.004>.
- [13] Choueiri TK, Vaishampayan U, Rosenberg JE, Logan TF, Harzstark AL, Bukowski RM, et al. Phase II and biomarker study of the dual MET/VEGFR2 inhibitor foretinib in patients with papillary renal cell carcinoma. *J Clin Oncol Off J Am Soc Clin Oncol* 2013;31:181–6. <https://doi.org/10.1200/JCO.2012.43.3383>.
- [14] Schöffski P, Wozniak A, Escudier B, Rutkowski P, Anthony A, Bauer S, et al. Crizotinib achieves long-lasting disease control in advanced papillary renal-cell carcinoma type 1 patients with MET mutations or amplification. EORTC 90101 CREATE trial. *Eur J Cancer* 2017;87:147–63. <https://doi.org/10.1016/j.ejca.2017.10.014>.
- [15] Choueiri TK, Plimack E, Arkenau H-T, Jonasch E, Heng DY, Powles T, et al. Biomarker-Based Phase II Trial of Savolitinib in Patients With Advanced Papillary Renal Cell Cancer. *J Clin Oncol* 2017;35:2993–3001. <https://doi.org/10.1200/JCO.2017.72.2967>.
- [16] Suarez Rodriguez C, Larkin JMG, Patel P, Valderrama BP, Rodriguez-Vida A, Glen H, et al. Overall survival results for durvalumab and savolitinib in metastatic papillary renal cancer. *J Clin Oncol* 2020;38:619–619. https://doi.org/10.1200/JCO.2020.38.6_suppl.619.
- [17] Choueiri TK, Heng DY, Lee JL, Cancel M, Verheijen RB, Mellemgaard A, et al. Efficacy of Savolitinib vs Sunitinib in Patients With MET-Driven Papillary Renal Cell Carcinoma: The SAVOIR Phase 3 Randomized Clinical Trial. *JAMA Oncol* 2020. <https://doi.org/10.1001/jamaoncol.2020.2218>.
- [18] Negrier S, Rioux-Leclercq N, Ferlay C, Gross-Goupil M, Gravis G, Geoffrois L, et al. Axitinib in first-line for patients with metastatic papillary renal cell carcinoma: Results of the multicentre, open-label, single-arm, phase II AXIPAP trial. *Eur J Cancer* 2020;129:107–16. <https://doi.org/10.1016/j.ejca.2020.02.001>.
- [19] Pal SK, Tangen C, Thompson IM, Balzer-Haas N, George DJ, Heng DY, et al. A comparison of sunitinib with cabozantinib, crizotinib, and savolitinib for treatment of advanced papillary renal cell carcinoma: a randomised, open-label, phase 2 trial. *Lancet Lond Engl* 2021;397:695–703. [https://doi.org/10.1016/S0140-6736\(21\)00152-5](https://doi.org/10.1016/S0140-6736(21)00152-5).
- [20] Gardie B, Remenieras A, Kattygnarath D, Bombled J, Lefevre S, Perrier-Trudova V, et al. Novel FH mutations in families with hereditary leiomyomatosis and renal cell cancer (HLRCC) and patients with isolated type 2 papillary renal cell carcinoma. *J Med Genet* 2011;48:226–34. <https://doi.org/10.1136/jmg.2010.085068>.
- [21] Gleeson JP, Nikolovski I, DiNatale RG, Zucker M, Knezevic A, Patil S, et al. Comprehensive Molecular Characterization and Response to Therapy in FH-Deficient Renal Cell Carcinoma. *Clin Cancer Res Off J Am Assoc Cancer Res* 2021. <https://doi.org/10.1158/1078-0432.CCR-20-4367>.
- [22] Network TCGAR. Comprehensive Molecular Characterization of Papillary Renal-Cell Carcinoma. <https://doi.org/10.1056/NEJMoa1505917> 2016. <https://doi.org/10.1056/NEJMoa1505917>.
- [23] Martinez Chanza N, Bossé D, Bilen MA, Geynisman DM, Balakrishnan A, Jain RK, et al. Cabozantinib (Cabo) in advanced non-clear cell renal cell carcinoma (nccRCC): A retrospective multicenter analysis. *J Clin Oncol* 2018;36:4579–4579. https://doi.org/10.1200/JCO.2018.36.15_suppl.4579.

- [24] Campbell MT, Bilen MA, Shah AY, Lemke E, Jonasch E, Venkatesan AM, et al. Cabozantinib for the treatment of patients with metastatic non-clear cell renal cell carcinoma: A retrospective analysis. *Eur J Cancer Oxf Engl* 1990 2018;104:188–94. <https://doi.org/10.1016/j.ejca.2018.08.014>.
- [25] Meeting Library | Results from a phase II study of bevacizumab and erlotinib in subjects with advanced hereditary leiomyomatosis and renal cell cancer (HLRCC) or sporadic papillary renal cell cancer. n.d. <https://meetinglibrary.asco.org/record/185952/abstract> (accessed June 1, 2020).
- [26] De Rosa V, Iommelli F, Monti M, Fonti R, Votta G, Stoppelli MP, et al. Reversal of Warburg Effect and Reactivation of Oxidative Phosphorylation by Differential Inhibition of EGFR Signaling Pathways in Non-Small Cell Lung Cancer. *Clin Cancer Res Off J Am Assoc Cancer Res* 2015;21:5110–20. <https://doi.org/10.1158/1078-0432.CCR-15-0375>.
- [27] Choi Y, Keam B, Kim M, Yoon S, Kim D, Choi JG, et al. Bevacizumab Plus Erlotinib Combination Therapy for Advanced Hereditary Leiomyomatosis and Renal Cell Carcinoma-Associated Renal Cell Carcinoma: A Multicenter Retrospective Analysis in Korean Patients. *Cancer Res Treat* 2019;51:1549–56. <https://doi.org/10.4143/crt.2019.086>.
- [28] Motzer RJ, Jonasch E, Michaelson MD, Nandagopal L, Gore JL, George S, et al. NCCN Guidelines Insights: Kidney Cancer, Version 2.2020: Featured Updates to the NCCN Guidelines. *J Natl Compr Canc Netw* 2019;17:1278–85. <https://doi.org/10.6004/jnccn.2019.0054>.
- [29] McDermott DF, Lee J-L, Ziobro M, Suarez C, Langiewicz P, Matveev VB, et al. Open-Label, Single-Arm, Phase II Study of Pembrolizumab Monotherapy as First-Line Therapy in Patients With Advanced Non-Clear Cell Renal Cell Carcinoma. *J Clin Oncol* 2021;JCO.20.02365. <https://doi.org/10.1200/JCO.20.02365>.
- [30] de Vries-Brilland M, Gross-Goupil M, Seegers V, Boughalem E, Beuselinck B, Thibault C, et al. Are immune checkpoint inhibitors a valid option for papillary renal cell carcinoma? A multicentre retrospective study. *Eur J Cancer Oxf Engl* 1990 2020;136:76–83. <https://doi.org/10.1016/j.ejca.2020.02.019>.
- [31] Goekbuget N. A Phase 2, Randomized, Open-Label Study of Nivolumab Combined With Ipilimumab Versus Standard of Care in Subjects With Previously Untreated and Advanced (Unresectable or Metastatic) Non-clear Cell Renal Cell Carcinoma (nccRCC). clinicaltrials.gov; 2020.
- [32] Pithukpakorn M, Wei M, Toure O, Steinbach PJ, Glenn GM, Zbar B, et al. Fumarate hydratase enzyme activity in lymphoblastoid cells and fibroblasts of individuals in families with hereditary leiomyomatosis and renal cell cancer. *J Med Genet* 2006;43:755–62. <https://doi.org/10.1136/jmg.2006.041087>.
- [33] National Cancer Institute (NCI). Phase I/II Trial of Vandetanib in Combination With Metformin in Subjects With HLRCC or SDH-Associated Kidney Cancer or Sporadic Papillary Renal Cell Carcinoma. clinicaltrials.gov; 2020.